


Screening for thoracic aortic pathology: Clinical practice in a single tertiary center

Lidia R. Bons MD¹ | Lucas Uchoa de Assis BSc¹ | Silvy Dekker MSc¹ |
Robert M. Kauling MD¹ | Judith A.A.E. Cuypers MD, PhD¹ |
Hence J.M. Verhagen MD, PhD² | Ricardo P.J. Budde MD, PhD³ |
Jolien W. Roos-Hesselink MD, PhD¹ 

¹Department of Cardiology, Erasmus Medical Center, Rotterdam, The Netherlands

²Department of Vascular Surgery, Erasmus Medical Center, Rotterdam, The Netherlands

³Department of Radiology and Nuclear Medicine, Erasmus Medical Center, Rotterdam, The Netherlands

Correspondence

J.W. Roos-Hesselink, Cardiology, Erasmus MC, Rg-435, Doctor Molewaterplein 40, 3015 GD Rotterdam, The Netherlands.
Email: j.roos@erasmusmc.nl

Funding information

This study was supported by the Dutch Heart Foundation (contract grant number: 2013T093).

Abstract

Objective: The aim is to present current clinical practice of thoracic aorta screening in a tertiary referral center. We identified how often imaging techniques were used for screening and established the value of transthoracic echocardiography (TTE) in comparison with computed tomography (CT) to detect aortic dilation. We also investigated which additional abnormalities of the heart, aorta or smaller arteries were discovered.

Design: All patients ≥ 15 years who visited our tertiary center in 2012-2016 for first thoracic aortic screening were retrospectively included. Diameters of the sinus of Valsalva (SoV) and maximum ascending aorta (AA) were compared between TTE and CT. The sensitivity and specificity of TTE to detect aortic dilation (≥ 40 mm) was assessed with CT as reference standard. Intracardiac abnormalities found with TTE and arterial abnormalities found with CT were identified.

Results: In total 349 patients (155 men, age 41 ± 15 years, 10% genetic mutation) were included. Screening was performed with TTE only in 35% and with TTE and CT in 65%. Patients who underwent TTE only were younger, had less often hypertension and less often a family history of aortic pathology. Although there was a good correlation between TTE and CT, the diameters measured with TTE were typically lower (SoV -1.0 , 95%CI -6.6 to 4.7 and AA -0.4 , 95%CI -6.5 to 5.8). Sensitivity of TTE for detecting aortic dilation was 61% (SoV) and 57% (AA) and specificity was 96% (SoV) and 100% (AA). Valve abnormalities, ventricular dilation or reduced ventricular function was found with TTE in 26 patients (7%). In 47 patients (13%) ascending aortic dilation was diagnosed and in 10 patients (4%) relevant peripheral arterial abnormalities were identified using CT.

Conclusions: Most often patients received both TTE and CT (65%). Since TTE showed a low sensitivity to detect aortic dilation, CT imaging is advised at least once in patients referred for thoracic aortic screening.

KEYWORDS

computed tomography, echocardiography, screening, thoracic aortic pathology

1 | INTRODUCTION

Thoracic aortic aneurysm (TAA) is typically clinically silent. Very often the first presentation is an acute aortic dissection or rupture with high rates of mortality.¹ The estimated prevalence of a TAA in the general population is 0.3%,² but there can be a genetic predisposition. Screening of patients at risk for thoracic aortic dilation (eg, family members, mutation carriers) is important to timely detect dilation and allow preventive intervention before dissection or rupture will occur. Persons who are referred for screening can undergo several possible imaging examinations to assess the thoracic aorta. Currently, transthoracic echocardiography (TTE), computed tomography (CT) and magnetic resonance imaging (MRI) are used for diagnostic imaging of the aorta. TTE excels in temporal resolution, is harmless, cheap and can be used in any clinical setting, but it will not show the entire thoracic aorta. Especially, the upper part of the ascending aorta and the arch may be hard to visualize. The primary strength of CT is the high spatial resolution, but the drawback is the radiation exposure and, for optimal visualization, need for the use of intravenous iodinated contrast. MRI falls between these extremes: it images the entire thoracic aorta, requires no radiation and can be performed without contrast administration. Current guidelines³⁻⁵ advise to offer screening to first-degree relatives of patients with a TAA, especially in case of a bicuspid aortic valve or Marfan syndrome. However, no specific imaging modality is advised for screening of the thoracic aorta, in contrast to the existing clear guidelines for screening for abdominal aortic aneurysms which favor ultrasound.^{6,7} The American Society of Echocardiography (ASE) and the European Association of Cardiovascular Imaging (AEI)⁴ choose TTE as first choice, but the European Society of Cardiology (ESC)³ prefers screening for aneurysms not only in the thoracic aorta, but also throughout the arterial tree (including cerebral arteries) with CT or MRI. The question remains whether the more expensive and potentially harmful CT examinations should be used and are necessary in all patients referred for screening. A relatively new concept which is entering clinical care is the "Choosing wisely" campaign initiated by the American Board of Internal Medicine Foundation (ABIM). The goal is to provide evidence-based care which is free from harm and truly necessary. Overuse of low-value services is a significant problem.^{8,9} To choose an appropriate imaging approach for screening in patients at risk for aortic pathology, the advantages and disadvantages of each imaging modality must be carefully considered. In our center, we use predominantly CT and TTE. The exact value of these examinations in screening for TAAs is not well known. Expected associated abnormalities, both cardiac and in the great arteries, may guide the choice of imaging modality. However, the prevalence of associated cardiac abnormalities and aneurysms in the great vessels has not been studied previously. The aim of this study was to describe current clinical practice of screening for thoracic aortic pathology in a tertiary center. We studied which imaging techniques were used for screening and aimed to establish the

accuracy of TTE in comparison with CT to detect aortic dilation in patients who underwent both examinations. We also investigated which additional abnormalities of the heart, aorta, or other great vessels were discovered.

2 | METHODS

All consecutive adults scheduled for screening of thoracic aortic disease in a specialized tertiary cardiology outpatient clinic between 2012 and 2016 were retrospectively included in this study. Patients are referred for aortic screening or follow-up and treatment of already existing (syndromes with) aortic pathology. Patients underwent no previous imaging investigations for screening of the thoracic aorta elsewhere. Inclusion criteria for our study were: (1) age ≥ 15 years, (2) first visit to the outpatient clinic of thoracic aortic disease and (3) screening as reason of referral. The decision which imaging modality was indicated for patients was based on clinical experience and preference of the treating physician (JR, JC, or RM). Demographic, clinical, and family data together with information about genetic testing¹⁰ were obtained from the electronic patient files. Hypertension, hypercholesterolemia, and diabetes mellitus were defined as current use of medication for that particular disease. The study complied with the Declaration of Helsinki and was approved by the medical ethical committee of the Erasmus Medical Center. Informed consent was not obliged.

2.1 | Aortic diameters

On CT, the aortic diameters were measured following a standard protocol at the level of the sinus of Valsalva (SoV), ascending aorta, aortic arch, and descending aorta. Both the ascending aorta (AA) and descending aorta (DA) were measured at the maximum diameter (mostly at the level of the left atrium or pulmonary bifurcation). On TTE, the diameters of the SoV and AA (largest diameter) were measured and compared with CT measurements.

2.2 | Transthoracic echocardiography

Standard two-dimensional TTE was performed by experienced sonographers, following a standard protocol. All studies were acquired using harmonic imaging on an iE33 or EPIQ7 ultrasound system (Philips Medical Systems, Best, The Netherlands) equipped with an $\times 5-1$ matrix-array transducer (composed of 3040 elements operating at 1-5 MHz). The aorta was measured in the standard parasternal long-axis view and acquisition of the long-axis view performed from a different intercostal space or at a different distance from the sternal border to improve the visualization of the ascending aorta.¹¹ The measurements were performed from leading edge-to-leading edge during diastole. The presence of a bicuspid aortic valve was assessed on TTE and classified as yes,

no or unclear. Aortic stenosis was defined as peak aortic velocity ≥ 2.5 m/s. Aortic regurgitation was graded by sonographers as mild, moderate or severe according to the EAE/ASE guidelines.¹² Septal wall thickness of ≥ 13 mm was identified as ventricular hypertrophy and a left ventricular diameter of ≥ 60 mm was identified as ventricular dilation. The transthoracic echocardiogram was analyzed using Curad off-line software (version 3.5.3.0, Wijk bij Duurstede, The Netherlands).

2.3 | Computed tomography

Contrast-enhanced CT scans of the entire aorta were obtained with standard acquisition protocols on a variety of scanners including both the thoracic and abdominal aorta until the femoral artery. Overall 202/226 (89%) of the scans were performed on a second or third generation dual source scanner (Flash, Drive and Force, Siemens Healthineers, Erlangen, Germany) most commonly with a high-pitch acquisition in 183/226 (81%) scans. For 193/226, the phase of the RR interval was available and ranged between 20% and 70%. The aortic diameters were measured using the double-oblique technique perpendicular to the vessel axis and the SoV was measured as the cusp-to-commissure distance, because this is the method most often used.⁴ Arterial anomalies were divided into aneurysm, stenosis, and dissection located in the thorax or abdomen. We used the following definitions for clinical relevant aneurysms: aortic root ≥ 40 mm,¹³ ascending and descending aorta ≥ 40 mm,¹³ pulmonary artery ≥ 30 mm,¹⁴ abdominal aorta ≥ 30 mm,¹⁵ splenic, celiac, hepatic, gastroduodenal, pancreaticoduodenal, gastric or mesenteric arteries ≥ 20 mm,^{16,17} iliac artery ≥ 25 mm¹⁸ and femoral artery ≥ 20 mm.¹⁹ In addition, congenital abnormalities such as a partial anomalous pulmonary venous return (PAPVR) were determined. Variants in human anatomy like aberrant subclavian artery (lusoria artery) were also identified.

2.4 | Statistical methods

All data are presented as mean with standard deviation when normally distributed, and in case of nonnormal distribution as medians with interquartile ranges. Data distribution was checked using histograms and the Shapiro-Wilk test. Comparison of normally distributed continuous variables was done using the Student's *t* test or, in case of a skewed distribution, the Mann-Whitney test. Categorical variables are presented as frequencies with percentages. Comparison of categorical variables was done using the chi-square test and in case of an expected count < 5 in one of the cells of the crosstable the Fisher's exact test was used. Differences between the diameter of the aorta at TTE and CT were tested with a paired *t* test and visualized with Bland-Altman plots.²⁰ The limits of agreement were calculated using the mean and standard deviation of the difference. Multivariable linear regression analysis was used to identify associations between aortic diameter and age, sex or aortic diameter on CT images. The sensitivity and specificity of TTE in diagnosing an aortic

dilation (≥ 40 mm) of the SoV or AA was calculated with CT as reference method. The IBM SPSS statistics 21.0 software (IBM, Armonk, New York) was used for data analysis. All statistical tests were two-sided and a *P* value below .05 was considered significant.

3 | RESULTS

3.1 | Study population

A total of 437 patients visited the outpatient clinic of thoracic aortic disease for the first time. Their age ranged from 15 to 82 years. In 81% (354/437) of all patients, the indication was screening. The other patients were referred because of an incidentally detected aortic enlargement ($n = 72$) or for follow-up of aortic disease discovered elsewhere ($n = 11$). Screening patients were divided in two groups: patients with only TTE and patients with both TTE and CT in our center. Due to limited numbers, patients who underwent only a CT ($n = 4$) or MRI ($n = 1$) were excluded.

The 349 (44% male, mean age 41 ± 15 years) remaining patients form the basis of this study. They were referred by the clinical geneticist (67%), general practitioner (24%), another specialized physician (7%), or an external cardiologist (2%). The reasons for screening were family history of thoracic aortic pathology in 208 patients (60%), family history of aneurysms or dissections in other vessels than the thoracic aorta in 27 patients (8%), family history of sudden cardiac death in 12 patients (3%), family history with a bicuspid aortic valve in 22 patients (6%), suspicion of a syndrome associated with aortic pathology in 60 patients (17%), and a newly diagnosed genetic mutation associated with aortic pathology in 20 patients (6%).

Of the 349 patients, 123 (35%) patients underwent only TTE during their visit and 226 (65%) patients underwent both TTE and CT imaging. In four patients, CT imaging was performed without contrast. Of all patients with CT imaging, the majority (95%) underwent CT imaging of both thorax and abdomen, while 12 patients had CT imaging of the thorax only. The baseline characteristics are shown in Table 1. In general, patients who had TTE only were younger, had lower blood pressure, less hypertension and less family members with an aortic aneurysm or dissection. In 108 (31%) of the patients genetic testing was performed, equally divided between the 2 patient groups. In total, 35 patients had a genetic mutation of which most were found in the FBN1 gene ($n = 5$), SMAD3 gene ($n = 6$), and TGFB3 gene ($n = 5$). These genetic mutations were either the reason for screening or found as a result of screening. In 132 of the 349 patients (38%) the family history was negative, 107 patients (31%) had a first-degree or second-degree family member with a TAA, 57 patients (16%) had a first-degree or second-degree family member with a thoracic aortic dissection and 53 patients (15%) had both aneurysm and dissection in their family history. As expected based on guidelines and clinical experience of physicians, patients with a family history of aortic aneurysm or dissection underwent a CT more often than patients without such a family history (69% vs 50%, $P < .001$).

TABLE 1 Baseline characteristics screening patients

	Total (n = 349)	Patients with echocardiography alone (n = 123)	Patients with echocardiography and CT imaging (n = 226)	P value
Age (y)	41 ± 15	32 ± 12	46 ± 15	.000
Female	194 (56%)	71 (58%)	123 (54%)	.553
Height (cm)	176 ± 11	178 ± 12	175 ± 11	.034
Weight (kg)	77 ± 17	73 ± 18	79 ± 16	.009
Systolic blood pressure (mm Hg)	130 ± 19	125 ± 16	133 ± 19	.000
Diastolic blood pressure (mm Hg)	81 ± 12	78 ± 11	83 ± 13	.001
Hypertension	44 (13%)	4 (3%)	40 (18%)	.000*
Hypercholesterolemia	7 (2%)	0 (0%)	7 (3%)	.055*
Diabetes mellitus type 2	7 (2%)	2 (2%)	5 (2%)	1.000*
Beta-blockers	25 (7%)	5 (4%)	20 (9%)	.098
Diuretics	27 (8%)	2 (2%)	25 (11%)	.001*
ACE inhibitors	12 (3%)	0 (0%)	12 (5%)	.010*

Values are given in mean ±SD or n (%).

*Fisher's exact test.

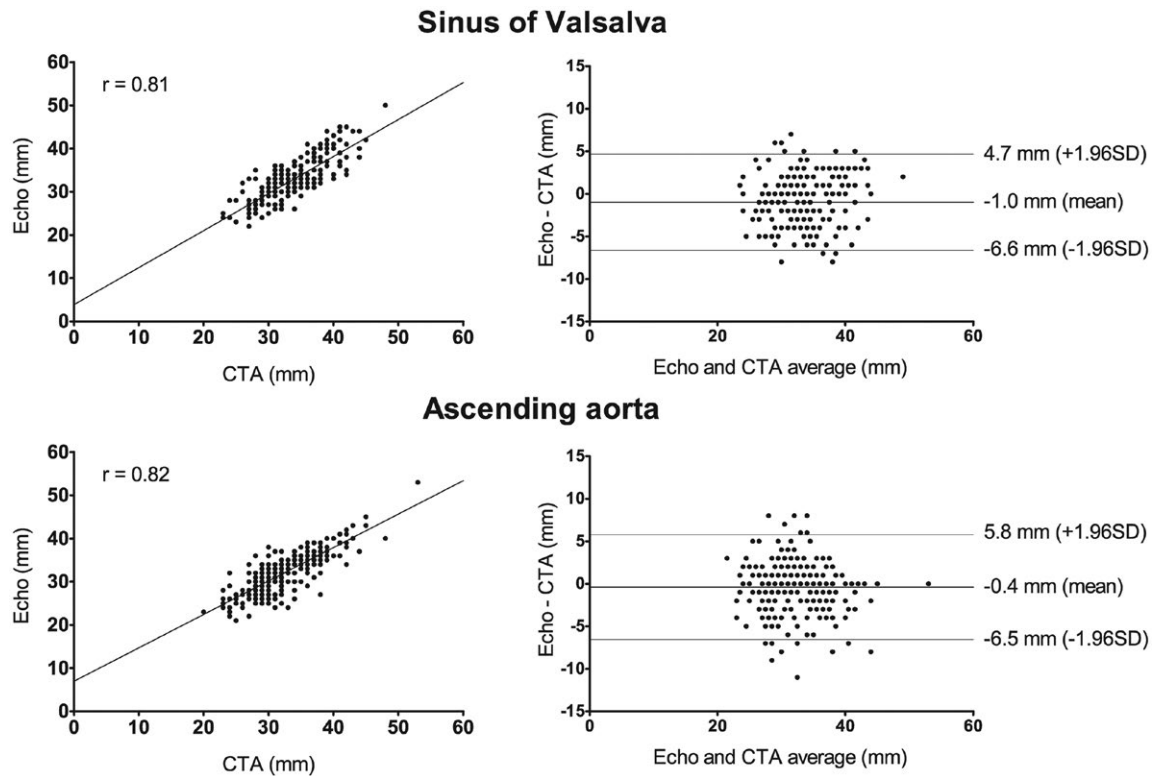


FIGURE 1 Bland-Altman plots of difference between echocardiography and computer tomography at the level of the sinus of Valsalva and the ascending aorta. Bland-Altman plots comparing aortic measurements performed using the leading-edge-to-leading-edge with echo and inner-edge-to-inner-edge with CT at the level of the sinus of Valsalva (mean difference -1.0 mm, n = 217) and ascending aorta (mean difference -0.4 mm, n = 221)

3.2 | Aortic diameter

In total, in 47 patients (13%) the proximal aorta (SoV or AA) was ≥ 40 mm on TTE or CT and in 2 patients (0.6%) it was ≥ 50 mm. In patients who underwent both TTE and CT, the diameter of the SoV was

significantly larger on CT compared to TTE (33.9 mm vs 32.9 mm, $P < .001$). However, the difference at the level of the AA was not significantly different (32.4 mm vs 32.0 mm, $P = .089$). Figure 1 shows Bland-Altman plots of measurements of the aorta with TTE and CT both at the level of the SoV and the AA. The diameter at the level

TABLE 2 Imaging findings of echocardiography and computed tomography in screening patients (n = 349)

	Echocardiography (n = 349)	Computed tomography (n = 226)
Bicuspid aortic valve	8 (2%)*	-
Aortic stenosis (>2.5 m/s)	2 (1%)	-
Aortic regurgitation (>mild)	2 (1%)	-
Other valve disease (>mild)	6 (2%)	-
Ventricular hypertrophy (septal wall ≥ 13 mm)	5 (1%)	-
Ventricular dilation (LV diameter ≥ 60 mm)	4 (1%)	-
Diameter sinus of Valsalva (mm)	32 \pm 6	33 \pm 6
Diameter ascending aorta (mm)	29 \pm 8	32 \pm 5
Diameter aortic arch (mm)	-	26 \pm 4
Diameter descending aorta (mm)	-	23 \pm 4
Any arterial anomaly or variant	-	35 (16%)
Clinical relevant arterial anomaly	-	10 (4%)

Values are given in mean \pm SD or n (%).

*In addition to this eight patients, we found six patients with unclear aortic valve morphology because of insufficient image quality of whom two have a high suspicion of a bicuspid aortic valve.

of the SoV could not be measured with echo in one patient due to insufficient image quality and with CT in four patients due to the absence of contrast. The ascending aorta could not be imaged with echo in nine cases because of unfavorable aortic anatomy in the chest or high BMI. At SoV level, the difference between TTE and CT was ≥ 5 mm in 14% with a maximum difference of 8 mm, while at AA level a difference of ≥ 5 mm was found in 14% with a maximum difference of 11 mm. With multiple linear regression analysis, age was positively associated with the difference in diameter between CT and echocardiography for both the level of the SoV ($P = .004$) and ascending aorta ($P = .006$). However, for both levels the absolute aortic diameter was negatively associated with the difference in diameter between CT and echocardiography ($P < .001$). This implies that with a smaller aortic diameter, we are more likely to find a large difference between the two modalities. For the ascending aorta, male gender was also associated with a larger difference between

the two modalities ($P = .020$). Sensitivity of TTE for detecting aortic dilation was 61% (SoV) and 57% (AA) and specificity was 96% (SoV) and 100% (AA).

3.3 | Additional findings on echocardiography and computed tomography

In Table 2, the outcomes of TTE and CT are summarized. In eight patients (2%), a BAV was found. Valve abnormalities including BAV (5%), ventricular hypertrophy (1%), and ventricular dilation (1%) were relatively rare.

In the 226 patients who had a CT scan, 38 arterial abnormalities were described by radiologists in 35 patients (15%) in addition to aortic aneurysms of the SoV or AA (Figure 2). Twenty-one of these arterial abnormalities were found in the abdomen (60%). Including only clinically relevant aneurysms, we found 11 abnormalities in 10 patients (4% of all patients): dissection of the renal artery in one patient, dilation of the pulmonary artery (≥ 30 mm) in six patients, dilation of the aortic arch in one patient, dilation of the abdominal aorta (32 mm) in one patient and one patient had a dilation of the femoral artery (36 mm) as well as a dilation of the abdominal aorta (32 mm). This last patient needed preventive surgery for the femoral artery aneurysm. Of the 10 patients with clinically relevant peripheral arterial abnormalities, six patients also showed a SoV or AA of ≥ 40 mm. All patients with clinically relevant abnormalities are shown in Table 3. The presence of an aneurysm of the proximal aorta was associated with vascular abnormalities, both "all abnormalities" ($P = .004$) and "clinically relevant abnormalities" ($P = .013$). The presence of a known genetic mutation or family history of aortic disease was not associated with vascular abnormalities ($P = .138$ and $P = .259$, respectively).

4 | DISCUSSION

In our tertiary center, the majority of the patients referred for aortic screening received both TTE and CT (65%). In our cohort, dilation (≥ 40 mm) of the aortic root or ascending aorta was found in 13%, intracardiac abnormalities were detected in 7%, and relevant other arterial abnormalities in 4%.

4.1 | Accuracy of TTE and CT to establish aortic dilation

The mean difference of the proximal aortic diameter measured with TTE vs CT was small, but large differences were found in individual patients with a difference of up to 8 mm for the SoV and up to 11 mm at the level of the ascending aorta. Although the specificity of TTE for detecting aortic dilation was good, the sensitivity was only 55%-60%, which implies that by imaging the ascending aorta in one plane only on 2DTTE, the true maximal diameter may easily be missed. This is in agreement with previous literature.^{21,22} One previous study looked at the ability of TTE to

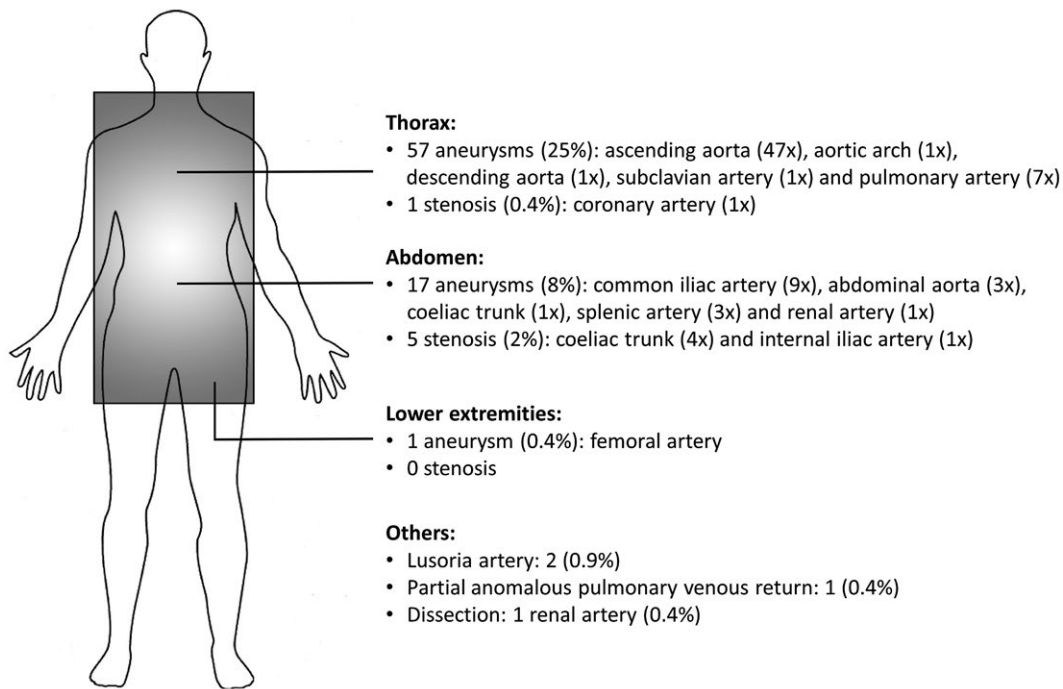


FIGURE 2 Vascular abnormalities or variants found with CT. Vascular abnormalities or variants found in scanned area (gray rectangle) with CT while patients came for thoracic aortic pathology screening. Thorax alone was scanned in 12 patients and in 214 patients both thorax and abdomen were scanned. When we only include the clinical relevant aneurysms, we found 11 abnormalities (4% of all patients)

identify an aneurysm of the aortic root or ascending aorta in patients with a bicuspid aortic valve.²³ In this paper, TTE sensitivity to detect aortic dilation (defined as SoV ≥ 35 mm and AA ≥ 38 mm) was 75% for the SoV and 47% for the AA with MRI as reference standard. The authors concluded that TTE often misses aortic dilation in patients with a bicuspid aortic valve. Our study confirms this in a more mixed population of patients referred for thoracic aortic screening.

We used the cusp-to-commissure method, because by CT or MRI the aortic root is measured most often between the inner edges from commissure to opposite sinus.⁴ There is still no consensus in the guidelines how to measure the aortic root at the level of the SoV. One study showed that the cusp-to-commissure diameter is best comparable with echocardiography,²⁴ while others show that the RCC-NCC cusp-to-cusp diameter show the best agreement with echocardiography.²⁵ When performing echocardiography the exact orientation of the measurement at the level of the SoV relative to the 3 sinuses highly depends on the orientation of the echo probe during the examination and the orientation of the aortic root itself in that individual. Therefore, often we don't know if the ultrasound image cuts through the cusp or commissure and this explains the discrepancies in aortic measurements between echo and CT.²⁶

In patients at risk for thoracic aortic pathology, the aim is to accurately identify aortic dilation and therefore an accurate and reliable imaging modality is warranted. In our opinion, CT or MRI meets these requirements better than TTE and should be used at least once for screening in all patients at risk for thoracic aortic aneurysm and/or dissection. Particularly in subjects with a more extended family

history of aneurysms or dissection in the more distal thoracic aorta, which is not visible with TTE, advanced imaging such as CT or MRI should be considered.

4.2 | Should TTE be a part of routine screening?

An argument in favor of using TTE as screening tool would be the ability to detect intracardiac abnormalities, including valve pathology and ventricular hypertrophy or dilation. In our study, concomitant cardiac abnormalities were rarely found on TTE. A bicuspid aortic valve was present in 2% of the patients, which is comparable to the general population.^{27,28} In our specific group of patients, at risk for thoracic aortic pathology, we expected it to be higher. The prevalence of aortic valve regurgitation in our group was also comparable to the prevalence found in the Framingham Heart Study (0%-2.3% depending on age).²⁹ Aortic stenosis was found even less often compared to data from a systematic review on aortic stenosis.³⁰ Other new findings were not discovered. In our view, the low frequency of concomitant intracardiac findings is not a valid argument to choose TTE as a primary screening tool.

4.3 | Additional vascular abnormalities on CT

In patients referred for screening who underwent CT, we found peripheral arterial pathology in 15%, predominantly located in the abdomen. Eleven of these pathologies (4% of all patients) were clinically relevant. We showed that aneurysms of the SoV and/or ascending aorta are associated with abnormalities in other intrathoracic,

TABLE 3 Ten patients with a clinically relevant arterial abnormality diagnosed with CT

Nr	Age, gender	Aortic diameters CT (mm)				Genetic mutation	Familial aneurysm	Familial dissection	Arterial abnormality
		SoV	AA	Arch	DA				
1	28, M	27	24	20	17	COL3a1	0	0	Dissection renal artery
2	58, F	30	30	27	23	No	1	0	Dilation pulmonary artery (32 mm)
3	66, F	42	43	39	24	No	1	0	Dilation pulmonary artery (45 mm)
4	69, M	35	34	31	26	SMAD3	0	0	Dilation pulmonary artery (33 mm)
5	48, M	44	42	30	28	No	1	1	Dilation pulmonary artery (35 mm)
6	60, M	39	42	27	29	No	1	1	Dilation pulmonary artery (40 mm)
7	75, F	*	48	33	29	No	1	1	Dilation pulmonary artery (41 mm)
8	63, F	33	38	40	27	No	1	1	Dilation aortic arch (40 mm)
9	62, M	32	34	28	28	No	0	0	Dilation abdominal aorta (32 mm)
10	62, M	44	45	39	29	No	1	0	Dilation femoral artery (36 mm) and abdominal aorta (32 mm)

Abbreviation: AA, ascending aorta; DA, descending aorta; SoV, sinus of Valsalva.

*Sinus of Valsalva could not be measured due to non-enhanced CT scan.

abdominal, or more peripheral arteries. This is well known for patients with *SMAD3* or *TGF β 3* mutation. In patients with abdominal aortic aneurysms, femoral or popliteal aneurysm are reported in up to 14%.³¹ However, data on the coexistence of peripheral pathology in the case of TAAs are scarce.³ Of course, the clinical decision to perform CT or not in these patients implies a selection bias.

4.4 | Which imaging technique in which patient?

Every patient referred for aortic screening should have an accurate measurement of aortic dimensions by CT or MRI. It has already been shown that the measurement of the thoracic aortic diameter is comparable between CT and MRI.³² Based on further family history or specific genetic mutation, an individual estimation should be made on the risk of intracardiac or peripheral vascular pathology. This should guide the decision to add TTE and choose between CT and MRI. In our center, we prefer using CT imaging instead of MRI, because the high spatial resolution allows simultaneous imaging of the smaller thoraco-abdominal arteries. Because connective tissue diseases like *SMAD3*³³ and Loeys-Dietz are recognized increasingly, imaging of both aorta and peripheral arteries is more frequently required. Indeed in current times the radiation dose is typically low and in our opinion the clinical relevance of correctly diagnosing aortic pathology warrants optimal imaging. Of course MRI has the great advantage of not exposing the patient to radiation at all and this technique should be used in children when possible. The 11 clinically relevant arterial abnormalities listed in Table 3 are located in the larger arteries and would likely have been picked up by an MRI vasculopathy study, which would be an argument for MRI.

In patients where aortic dilatation is diagnosed follow-up is needed to identify further growth of the aorta. In patients where echocardiography is able to visualize the aortic root and ascending aorta sufficiently, echocardiography can be used as imaging tool

during follow-up. However, when TTE cannot be used, MRI is preferred, especially in younger patients. Preferably, follow-up should be performed with the same modality using the same technique. When the aortic diameter approaches the thresholds for preventive intervention, more accurate imaging of the aorta using CT (or MRI) is indicated to identify the exact aortic diameter and aortic anatomy before intervention is considered.

In conclusion, we found that CT performs better than TTE in screening for aortic dilation. We advise to use CT (or MRI) for screening in all patients at risk for thoracic aortic disease. Extra-aortic arterial abnormalities were found relatively often with CT, increasing the diagnostic value of CT as an imaging tool. Intracardiac abnormalities were not common in patients who were sent for screening of thoracic aortic pathology. Although TTE is a suboptimal imaging technique for aortic screening, it may be used to detect intracardiac abnormalities in selected cases such as a family history of BAV. For ongoing surveillance of patients with aortic dilatation, further research is needed to determine the best imaging strategy for ongoing surveillance.

CONFLICT OF INTEREST

None.

AUTHOR CONTRIBUTIONS

LR Bons, L. Uchoa de Assis, S. Dekker, RPJ Budde, and JW Roos-Hesselink contributed to the concept/design, data analysis/interpretation, and drafting of the article.

RM Kauling and JAAE Cuypers contributed to data collection and writing.

HJM Verhagen contributed to the concept/design, critical revision of the article, and approval of the article.

ORCID

Jolien W. Roos-Hesselink  <http://orcid.org/0000-0002-6770-3830>

REFERENCES

- Melvinsdottir IH, Lund SH, Agnarsson BA, Sigvaldason K, Gudbjartsson T, Geirsson A. The incidence and mortality of acute thoracic aortic dissection: results from a whole nation study. *Eur J Cardiothorac Surg*. 2016;50(6):1111-1117.
- Kalsch H, Lehmann N, Mohlenkamp S, et al. Body-surface adjusted aortic reference diameters for improved identification of patients with thoracic aortic aneurysms: results from the population-based Heinz Nixdorf Recall study. *Int J Cardiol*. 2013;163(1):72-78.
- Erbel R, Aboyans V, Boileau C, et al. 2014 ESC Guidelines on the diagnosis and treatment of aortic diseases: Document covering acute and chronic aortic diseases of the thoracic and abdominal aorta of the adult. The Task Force for the Diagnosis and Treatment of Aortic Diseases of the European Society of Cardiology (ESC). *Eur Heart J*. 2014;35(41):2873-2926.
- Goldstein SA, Evangelista A, Abbara S, et al. Multimodality imaging of diseases of the thoracic aorta in adults: from the American Society of Echocardiography and the European Association of Cardiovascular Imaging: endorsed by the Society of Cardiovascular Computed Tomography and Society for Cardiovascular Magnetic Resonance. *J Am Soc Echocardiogr*. 2015;28(2):119-182.
- Lang RM, Badano LP, Mor-Avi V, et al. Recommendations for cardiac chamber quantification by echocardiography in adults: an update from the American Society of Echocardiography and the European Association of Cardiovascular Imaging. *Eur Heart J Cardiovasc Imaging*. 2015;16(3):233-270.
- U.S. Preventive Services Task Force. Screening for abdominal aortic aneurysm: recommendation statement. *Ann Intern Med*. 2005;142(3):198-202.
- Simoni G, Pastorino C, Perrone R, et al. Screening for abdominal aortic aneurysms and associated risk factors in a general population. *Eur J Vasc Endovasc Surg*. 1995;10(2):207-210.
- Bishop TF, Cea M, Miranda Y, et al. Academic physicians' views on low-value services and the choosing wisely campaign: a qualitative study. *Healthc (Amst)*. 2017;5(1-2):17-22.
- Kline KP, Shaw L, Beyth RJ, et al. Perceptions of patients and providers on myocardial perfusion imaging for asymptomatic patients, choosing wisely, and professional liability. *BMC Health Serv Res*. 2017;17(1):553.
- Brownstein AJ, Ziganshin BA, Kuivaniemi H, Body SC, Bale AE, Elefteriades JA. Genes associated with thoracic aortic aneurysm and dissection: an update and clinical implications. *Aorta (Stamford)*. 2017;5(1):11-20.
- Lang RM, Badano LP, Mor-Avi V, et al. Recommendations for cardiac chamber quantification by echocardiography in adults: an update from the American Society of Echocardiography and the European Association of Cardiovascular Imaging. *Eur Heart J Cardiovasc Imaging*. 2015;16(3):233-270.
- Lancellotti P, Tribouilloy C, Hagendorff A, et al. Recommendations for the echocardiographic assessment of native valvular regurgitation: an executive summary from the European Association of Cardiovascular Imaging. *Eur Heart J Cardiovasc Imaging*. 2013;14(7):611-644.
- Hiratzka LF, Bakris GL, Beckman JA, et al. 2010 ACCF/AHA/AATS/ACR/ASA/SCA/SCAI/SIR/STS/SVM guidelines for the diagnosis and management of patients with Thoracic Aortic Disease: a report of the American College of Cardiology Foundation/American Heart Association Task Force on Practice Guidelines, American Association for Thoracic Surgery, American College of Radiology, American Stroke Association, Society of Cardiovascular Anesthesiologists, Society for Cardiovascular Angiography and Interventions, Society of Interventional Radiology, Society of Thoracic Surgeons, and Society for Vascular Medicine. *Circulation*. 2010;121(13):e266-e369.
- Truong QA, Massaro JM, Rogers IS, et al. Reference values for normal pulmonary artery dimensions by noncontrast cardiac computed tomography: the Framingham Heart Study. *Circ Cardiovasc Imaging*. 2012;5(1):147-154.
- Moll FL, Powell JT, Fraedrich G, et al. Management of abdominal aortic aneurysms clinical practice guidelines of the European society for vascular surgery. *Eur J Vasc Endovasc Surg*. 2011;41(1):S1-S58.
- Huang YK, Hsieh HC, Tsai FC, Chang SH, Lu MS, Ko PJ. Visceral artery aneurysm: risk factor analysis and therapeutic opinion. *Eur J Vasc Endovasc Surg*. 2007;33(3):293-301.
- Lakin RO, Bena JF, Sarac TP, et al. The contemporary management of splenic artery aneurysms. *J Vasc Surg*. 2011;53(4): 958-965.
- Khosa F, Krinsky G, Macari M, Yucel EK, Berland LL. Managing incidental findings on abdominal and pelvic CT and MRI, Part 2: white paper of the ACR Incidental Findings Committee II on vascular findings. *J Am Coll Radiol*. 2013;10(10):789-794.
- Hirsch AT, Haskal ZJ, Hertzner NR, et al. ACC/AHA 2005 Practice Guidelines for the management of patients with peripheral arterial disease (lower extremity, renal, mesenteric, and abdominal aortic): a collaborative report from the American Association for Vascular Surgery/Society for Vascular Surgery, Society for Cardiovascular Angiography and Interventions, Society for Vascular Medicine and Biology, Society of Interventional Radiology, and the ACC/AHA Task Force on Practice Guidelines (Writing Committee to Develop Guidelines for the Management of Patients With Peripheral Arterial Disease): endorsed by the American Association of Cardiovascular and Pulmonary Rehabilitation; National Heart, Lung, and Blood Institute; Society for Vascular Nursing; TransAtlantic Inter-Society Consensus; and Vascular Disease Foundation. *Circulation*. 2006;113(11):e463-e654.
- Bland JM, Altman DG. Statistical methods for assessing agreement between two methods of clinical measurement. *Lancet*. 1986;1(8476):307-310.
- Tamborini G, Galli CA, Maltagliati A, et al. Comparison of feasibility and accuracy of transthoracic echocardiography versus computed tomography in patients with known ascending aortic aneurysm. *Am J Cardiol*. 2006;98(7):966-969.
- Tsang JF, Lytwyn M, Farag A, et al. Multimodality imaging of aortic dimensions: comparison of transthoracic echocardiography with multidetector row computed tomography. *Echocardiography*. 2012;29(6):735-741.
- Tsai SF, Trivedi M, Daniels CJ. Comparing imaging modalities for screening aortic complications in patients with bicuspid aortic valve. *Congenit Heart Dis*. 2012;7(4):372-377.
- Burman ED, Keegan J, Kilner PJ. Aortic root measurement by cardiovascular magnetic resonance: specification of planes and lines of measurement and corresponding normal values. *Circ Cardiovasc Imaging*. 2008;1(2):104-113.
- Rodriguez-Palomares JF, Teixido-Tura G, Galuppo V, et al. Multimodality assessment of ascending aortic diameters: comparison of different measurement methods. *J Am Soc Echocardiogr*. 2016;29(9):819-826.e4.
- Mori S, Anderson RH, Tahara N, et al. The differences between bisecting and off-center cuts of the aortic root: the three-dimensional anatomy of the aortic root reconstructed from the living heart. *Echocardiography*. 2017;34(3):453-461.
- Basso C, Boschello M, Perrone C, et al. An echocardiographic survey of primary school children for bicuspid aortic valve. *Am J Cardiol*. 2004;93(5):661-663.

28. Roberts WC. The congenitally bicuspid aortic valve. A study of 85 autopsy cases. *Am J Cardiol.* 1970;26(1):72-83.
29. Singh JP, Evans JC, Levy D, et al. Prevalence and clinical determinants of mitral, tricuspid, and aortic regurgitation (the Framingham Heart Study). *Am J Cardiol.* 1999;83(6):897-902.
30. Coffey S, Cox B, Williams MJ. The prevalence, incidence, progression, and risks of aortic valve sclerosis: a systematic review and meta-analysis. *J Am Coll Cardiol.* 2014;63(25):2852-2861.
31. Diwan A, Sarkar R, Stanley JC, Zelenock GB, Wakefield TW. Incidence of femoral and popliteal artery aneurysms in patients with abdominal aortic aneurysms. *J Vasc Surg.* 2000;31(5):863-869.
32. Jabbour A, Ismail TF, Moat N, et al. Multimodality imaging in transcatheter aortic valve implantation and post-procedural aortic regurgitation: comparison among cardiovascular magnetic resonance, cardiac computed tomography, and echocardiography. *J Am Coll Cardiol.* 2011;58(21):2165-2173.
33. van de Laar IM, Oldenburg RA, Pals G, et al. Mutations in SMAD3 cause a syndromic form of aortic aneurysms and dissections with early-onset osteoarthritis. *Nat Genet.* 2011;43(2):121-126.

How to cite this article: Bons LR, Uchoa de Assis L, Dekker S, et al. Screening for thoracic aortic pathology: Clinical practice in a single tertiary center. *International Journal of Social Welfare.* 2018;13:988-996. <https://doi.org/10.1111/chd.12663>