

# Acute and long-term effects of endovascular debanding of pulmonary arteries in a swine model

Michael Perez, MD<sup>1</sup> | Tk Susheel Kumar, MD<sup>2</sup> | Deepthi Hoskoppal, MD<sup>3</sup> |  
Yada Akkhwattanakul, DVM<sup>4</sup> | Kimberly Allen, RN<sup>5</sup> |  
Christopher J. Knott-Craig<sup>2</sup> | Benjamin Rush Waller, MD<sup>1</sup> |  
Shyam Sathanandam, MD<sup>1</sup>

<sup>1</sup>Department of Pediatrics, Division of Pediatric Cardiology, University of Tennessee Health Science Center, Memphis, Tennessee, USA

<sup>2</sup>Department of Surgery, University of Tennessee Health Science Center, Memphis, Tennessee, USA

<sup>3</sup>Department of Pathology, University of Tennessee Health Science Center, Memphis, Tennessee, USA

<sup>4</sup>Department of Veterinary Medicine, University of Tennessee Health Science Center, Memphis, Tennessee, USA

<sup>5</sup>LeBonheur Children's Hospital, Memphis, Tennessee, USA

## Correspondence

Shyam Sathanandam, MD, 848 Adams Avenue, Memphis, TN 38103, USA.  
Email: shyam78@gmail.com

## Abstract

**Objectives:** The primary objective of this study was to demonstrate that pulmonary artery (PA) debanding via cardiac catheterization using balloon angioplasty is feasible and safe in swine. The secondary objectives were to determine the acute and long-term effects of this therapy.

**Design:** This is a chronic survival experimental study in newborn swine.

**Background:** PA bands are used in infants for transient palliation of congenital heart defects with excessive pulmonary blood flow. Although rare, if these defects should close spontaneously or become hemodynamically insignificant, a sternotomy and occasionally cardiopulmonary bypass may still be required for band removal. Alternatively, debanding could be accomplished through less invasive methods.

**Interventions:** The main pulmonary artery was banded in three piglets, and the left pulmonary artery in five piglets via mini-thoracotomy at a mean weight of 2.5 kg. Following a threefold increase in weight, the piglets underwent PA debanding via balloon angioplasty. Four piglets were sacrificed to evaluate the acute effects. The remainder were followed to evaluate long-term effects. Histopathology was performed on all piglets.

**Outcome measures:** Reintervention rates. Histopathologic consequences of high pressure balloon angioplasty used for PA debanding acutely and after reinterventions.

**Results:** Debanding was performed at a mean weight of  $8.1 \pm 2.23$  kg. The median preintervention gradient across the band was 18 mm Hg. Debanding was successful in all piglets. The median postintervention gradient was 3.5 mm Hg. All piglets in the long-term model required reinterventions for recurrent stenosis at mean weights of  $26 \pm 1.6$  and  $61 \pm 3.2$  kg. Histopathology demonstrated vessel wall injury in only one piglet.

**Conclusions:** Endovascular PA debanding can be safely achieved in a swine model. Angioplasty following debanding may be necessary for recurrent stenosis. This catheter-based therapy may provide a less-invasive alternative to surgery.

## KEYWORDS

animal models, balloon angioplasty, pulmonary artery band, vessel injury

## 1 | INTRODUCTION

Pulmonary artery bands (PAB) were introduced in the 1950s for the palliation of congenital heart defects with excessive pulmonary blood flow.<sup>1</sup> This procedure continues to be used even today for transient palliation, most commonly for ventricular septal defects (VSD). Typically, PAB are taken down after a patient has been deemed ready for more definitive cardiac repair. Rarely, take down of the PAB would be indicated if there is spontaneous defect closure or the shunt lesion becomes smaller and thus hemodynamically insignificant. Lastly, in certain rare instances, pulmonary artery banding may be performed in patients with significant comorbidities that preclude definitive cardiac repair. In such situations, pulmonary blood flow may become overly restrictive over time and require band take down. Debanding is traditionally accomplished via a sternotomy and PAB suture ligation.<sup>2</sup> Occasionally, cardiopulmonary bypass is required for debanding due to significant adjacent vessel stenosis requiring resection and re-anastomosis.<sup>2</sup> It would be advantageous if pulmonary artery debanding could be accomplished through less invasive methods in the clinical scenario, albeit limited, where intracardiac surgery is not required following band removal. Cardiac catheterization offers the opportunity for pulmonary artery debanding through balloon angioplasty.

There have been few studies to date describing main pulmonary artery (MPA) debanding via high pressures balloons in both animal models and in children.<sup>3–6</sup> These studies demonstrate the potential for endovascular pulmonary artery debanding as an alternative to surgical removal. However, the feasibility and safety of this procedure has not been established. None of the previous studies have evaluated the acute and long-term effects of endovascular debanding on the pulmonary arteries. These reports involved debanding of the MPA. However, none have evaluated debanding the branch pulmonary arteries. This has become more popular with the advent of the hybrid-Norwood procedure,<sup>7,8</sup> but isolated debanding without other cardiac interventions in such a scenario would be unique and has not been reported. Long-term outcomes evaluating the prevalence of recurrent stenosis and vessel growth after debanding are also limited. Therefore, despite its sporadic use, endovascular debanding following band placement around either the main or branch pulmonary artery is not an established practice. The primary objective of this study was to determine the feasibility and safety of endovascular pulmonary artery debanding in a growing animal model. The secondary objective was to determine the acute and long-term effects of this procedure on the pulmonary arteries.

## 2 | METHODS

Approval for this study was obtained from the Institutional Animal Care and Use Committee of University of Tennessee Health Science Center and the Medical Education and Research Institute in Memphis, Tennessee. The domestic farm pig was chosen as the animal model for this study as it has a circulatory system similar to the human and it grows rapidly to an average adult human size within 6 mo of age.<sup>9,10</sup>

For all surgical and cardiac catheterizations, the piglets were intubated with an appropriate sized endotracheal tube by the veterinary

anesthesiologist. A peripheral vein catheter was placed through which normal saline was administered throughout the procedures. Anesthesia was induced and maintained with isoflurane. Arterial blood gases and activated clotting times (ACT) were measured every 30 min. The animals were mechanically ventilated to achieve a normal pH and arterial CO<sub>2</sub> tension. Anesthesia was determined to be adequate through the evaluation of EKG, blood pressure and pulse oximetry. Pancuronium was administered at a rate of 0.2 mg/kg/h throughout the length of the procedures. All procedures were performed using universal sterile precautions.

### 2.1 | Pulmonary artery band placement

The initial procedure consisted of surgically placing PABs in eight neonatal piglets at 2–4 wk of age. An MPA band was applied in three piglets and the left pulmonary artery (LPA) was banded in five piglets. The piglets were placed in the right lateral decubitus position. A left posterolateral thoracotomy incision was used to enter the left fourth intercostal space. The mediastinal pleura was opened over the descending thoracic aorta to identify the descending thoracic aorta and the LPA adjacent to it. The left vagus and the left recurrent laryngeal nerve were carefully preserved. The pericardium was opened to visualize the main or left pulmonary artery. Polyethylene terephthalate bands were placed around either the MPA or the LPA and tightened in the same fashion as in human patients by a pediatric cardiovascular surgeon. The band around the MPA/LPA was tightened to achieve a 20–25% reduction in the original vessel diameter while making sure the hemodynamics remained stable. Once the appropriate tightness of the band was achieved, it was sutured to the adventitia using 6-0 Prolene sutures. Square knots were placed to secure the band in place and minimize band migration. The pericardium was not closed. An 8 French chest tube was placed in the left pleural space. The muscles were closed in layers using continuous 3-0 Vicryl sutures. The subcutaneous tissue was closed using continuous 3-0 Vicryl. The skin was closed using continuous 4-0 Monocryl suture. The piglets received one dose of intravenous Cefazolin during the procedure and two additional intramuscular doses 8 h apart following the procedure. The chest tubes were removed on the same day of the procedure. Following the procedure, the piglets were extubated and transferred to a warming mat in a pen located in a temperature controlled area.

### 2.2 | Interprocedural observation

Assessment for weight gain and complete physical exams were performed weekly. Echocardiograms were performed every 2 wk to evaluate gradients across the PAB in each piglet.

### 2.3 | Endovascular debanding

Following a threefold increase in weight, the piglets underwent the next staged experiment consisting of pulmonary artery debanding via balloon angioplasty. For each piglet, ultrasound guided percutaneous access of the femoral artery and vein was performed. A 5 French sheath with a side-arm was placed into the accessed vein and a 4 French sheath into the artery. The side-arm of the venous sheath was used as a central venous line for the purpose of administering fluids

TABLE 1 Pulmonary artery band placement and subsequent debanding

Pig <sup>a</sup>	Band site	Weight band placement (kg)	Weight debanding (kg)	Band gradient (mm Hg)	PA band diameter <sup>b</sup> (mm)	Adjacent PA diameter (mm) <sup>c</sup>	Debanding balloon pressure <sup>d</sup> (atm)	Balloon size (mm)	Post-debanding gradient (mm Hg) <sup>e</sup>	Post-debanding diameter <sup>f</sup> (mm)
A1	MPA	2.5	5.1	21	2.6	9.6	10	8	13	3.8
A2	LPA	2.4	8.1	7	2.9	7.9	16	8	0	5.1
A3	MPA	2.7	12.5	28	3.3	12.9	14	8	5	4.4
A4	LPA	2.9	9	18	1.9	4.3	10	4	0	3.2
C1	LPA	2.5	7.6	14	2.5	6.3	10	8	2	4.5
C2	LPA	2.6	8.2	12	1.8	5.4	14	6	0	5.3
C3	MPA	2.5	5.8	17	6.2	14.3	10	12	9	6.9
C4	LPA	2.4	8.5	20	1.6	4.6	10	5	7	3.9

<sup>a</sup>The four pigs belonging to the acute arm of the study are labeled A, and those belonging to the chronic arm are labeled C.

<sup>b</sup>The diameter of the pulmonary artery at the banded site, measured angiographically.

<sup>c</sup>The diameter of the pulmonary artery adjacent to the banded area. In the case of MPA bands, this represents the distal MPA prior to bifurcation of the branch pulmonary arteries. In the case of an LPA band, this represents the distal LPA prior to any branch lobar segments.

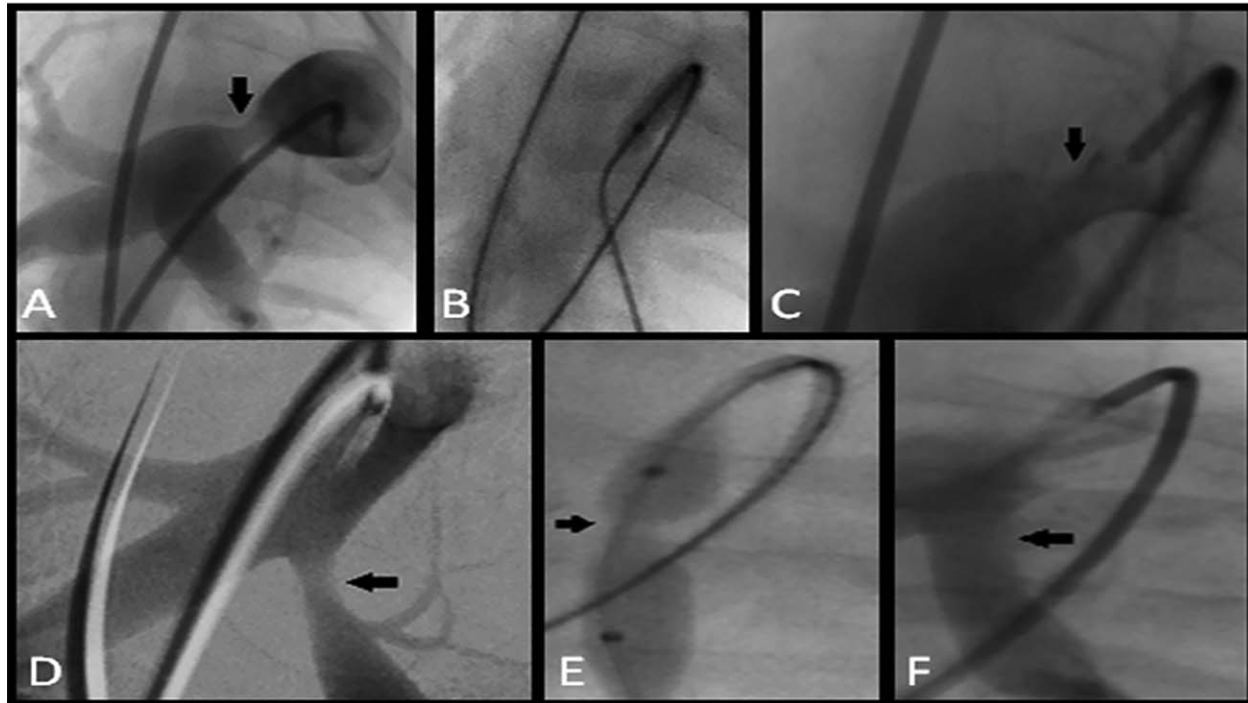
<sup>d</sup>The balloon pressure required to result in the angiographic evidence of debanding, previously described in this article as the "pop."

<sup>e</sup>Pressure difference measured across the previously banded site immediately following debanding via balloon angioplasty.

<sup>f</sup>The diameter of the pulmonary artery at the previously banded site, measured angiographically.

and medications as necessary. The side arm of the arterial sheath was connected to a pressure transducer for continuous blood pressure monitoring and blood sampling. Following vascular access, 100 U/kg of intravenous heparin was administered to maintain ACT between 20–

250 s with additional boluses given as needed. An angiographic catheter was introduced through the venous sheath and advanced to the pulmonary arteries under fluoroscopic guidance. Angiography of the main and branch pulmonary arteries were performed using Iodine



**FIGURE 1** Pulmonary artery debanding in acute model. (A) The band was placed on the main pulmonary artery in this piglet as noted in this angiogram. The banded site is shown by the arrow. (B) Balloon angioplasty across the banded site. (C) Angiogram shows the presence of residual stenosis (arrow) across the previously banded area in this pig. (D) A separate pig in which a band was placed on the proximal left pulmonary artery. This is demonstrated by the arrow. (E) The waist (arrow) produced in the balloon as it was inflated. The waist in the balloon subsequently disappeared upon debanding. (F) The postdebanding angiogram shows no residual stenosis across the previously banded site (arrow)

TABLE 2 Repeat cardiac catheterization findings in chronic arm

Weight repeat cath (kg)	PA gradient (mm Hg) <sup>a</sup>	PA diameter (mm) <sup>b</sup>	Adjacent PA diameter (mm) <sup>c</sup>	Postangioplasty gradient (mm Hg)	Postangioplasty PA diameter (mm) <sup>b</sup>	Weight terminal cath (kg)	PA gradient (mm Hg) <sup>a,f</sup>	PA diameter (mm) <sup>b,f</sup>	Adjacent PA diameter (mm) <sup>c,f</sup>	Postangioplasty gradient (mm Hg) <sup>f</sup>	Postangioplasty PA diameter (mm) <sup>b,f</sup>
26	11	3.2	7.6	4	4.5	58	6	4.1	9	6	6
26	7	4.4	6.3	0	7.1	N/A <sup>e</sup>	N/A <sup>e</sup>	N/A <sup>e</sup>	N/A <sup>e</sup>	N/A <sup>e</sup>	N/A <sup>e</sup>
24	13	6.9	18	13	8.2	64.5	6	16	24	1	20
28	6	4.9	6.4	N/A <sup>d</sup>	N/A <sup>d</sup>	61	7	6.2	9	4	7.9

<sup>a</sup>The blood pressure gradient obtained across the site of the pulmonary artery that was previously banded.

<sup>b</sup>The smallest diameter of the pulmonary artery of the previously banded site. This was determined and measured angiographically.

<sup>c</sup>The diameter of the pulmonary artery adjacent to the previously banded area. In the case of MPA bands, this represents the distal MPA prior to bifurcation of the branch pulmonary arteries. In the case of an LPA band, this represents the distal LPA prior to any branch lobar segments.

<sup>d</sup>C4 did not require angioplasty due to the low gradient across the previously banded area combined with the absence of significant residual stenosis angiographically.

<sup>e</sup>C2 did not have a terminal (3<sup>rd</sup>) catheterization as the animal died following the second procedure secondary to complications from an unrelated experimental study.

<sup>f</sup>The measured findings during the third and final cardiac catheterization.

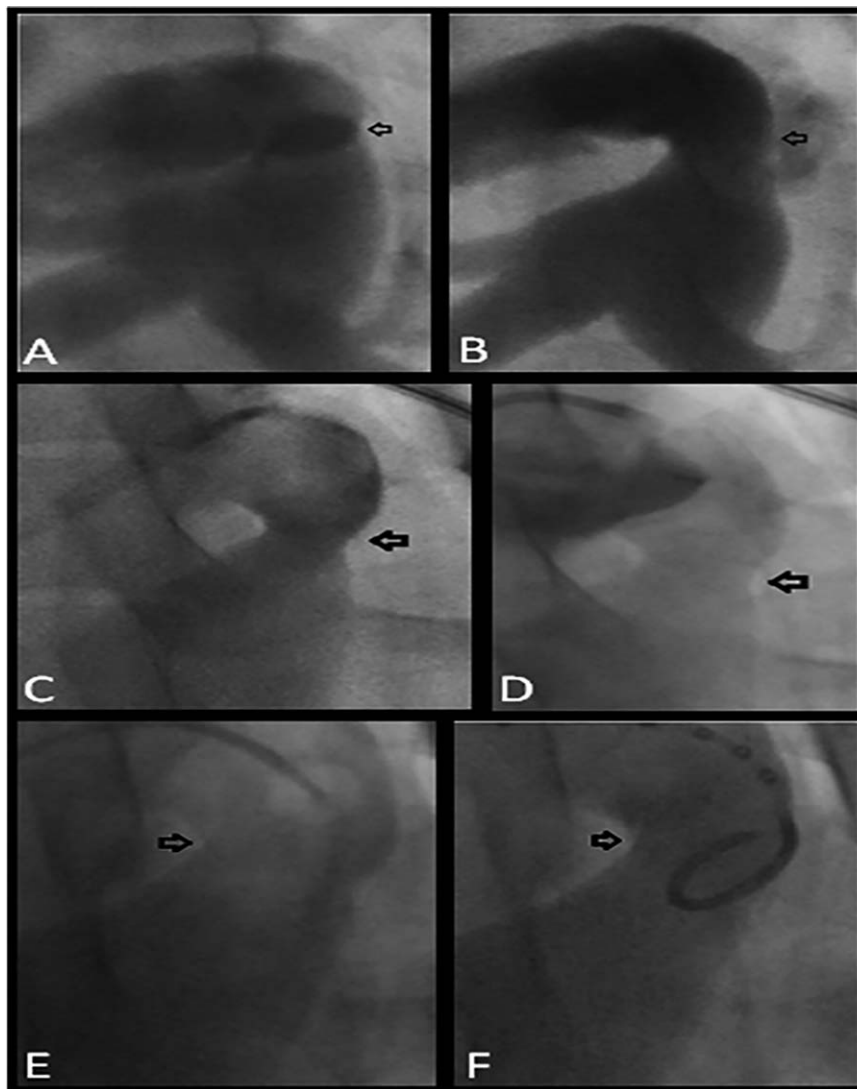
based Optiray contrast. Measurements of these vessels were obtained at the band site as well as the adjacent vessel distal to the band location and the proximal RPA at the level of the hilum. Arterial blood pressure measurements were recorded by connecting the arterial catheter to pressure monitors. The PAB gradient was measured by a pressure pull-back across the band site using an end-hole catheter. A 0.035" wire was placed through an end-hole catheter through the banded pulmonary artery. Over this wire a high pressure angioplasty balloon, such as a Conquest<sup>®</sup>, Atlas<sup>®</sup>, or Dorado<sup>®</sup> balloon (Bard Peripheral Vascular, Inc., Tempe, AZ), was introduced up to the level of the PAB. The balloon was infiltrated with diluted contrast and was dilated until the band suture was loosened. Successful debanding was determined by the sudden disappearance of a waist in the balloon, a "pop," at the banded site by the use of fluoroscopy during balloon inflation. The balloons were not inflated beyond their rated burst pressure. If debanding was not accomplished initially, this step was repeated by upsizing the balloon by 2 mm increments until a pop was seen. Debanding was deemed unsuccessful if the fluoroscopic pop did not occur after serial dilation up to a maximal balloon diameter, which was defined as the diameter that equals the immediately adjacent distal vessel diameter. The balloon size that ultimately achieved debanding in each case was documented to calculate a balloon size to PA stenosis diameter ratio as well as a balloon size to adjacent vessel diameter ratio.

## 2.4 | Study design

Four piglets were euthanized at this stage to evaluate the acute effects of debanding (acute arm). Necropsy was performed immediately to evaluate for vessel contusion, rupture, aneurysm or bleeding. Excisional biopsies were taken of the previously banded segments of the pulmonary arteries from each pig. The excised vessels were flushed and fixed in 10% neutral buffered formalin and sent for histopathologic examination. The other four piglets were followed to evaluate the long-term effects (chronic arm) and underwent repeat catheterization studies after being allowed to grow. These piglets were extubated and transferred back to a warming mat in a pen and followed for weight gain weekly as previously described. Surveillance echocardiograms were also performed on all four piglets belonging to the chronic arm of the study.

## 2.5 | Repeat catheterization

As part of the study protocol, a repeat catheterization was performed after 1–2 mo of growth in the four piglets belonging to the chronic arm of the study using the previously described steps taken in the debanding process. Blood pressure gradients across the previously banded sites were measured and angiography was again performed. Recurrent stenosis was determined as a  $\geq 30\%$  angiographic stenosis compared to the adjacent vessel wall diameter or by a pressure pullback gradient of  $\geq 10$  mm Hg. Percent stenosis was calculated as  $1 - (\text{PAB diameter} / \text{adjacent vessel diameter})$ . In cases in which there was criteria for recurrent stenosis, angioplasty of the stenotic area was performed as



**FIGURE 2** Pulmonary artery debanding of MPA in chronic model. (A) A pig belonging to the chronic arm of the study in which an MPA band was placed, which is shown by the arrow. (B) The same pulmonary artery following balloon angioplasty with resultant debanding as evidenced by the lack of discrete stenosis (arrow). (C) There is residual stenosis noted at the beginning of the first follow-up catheterization in this piglet (arrow). (D) There is improvement of the stenosis (arrow) after balloon angioplasty. (E) There is mild residual stenosis noted at the beginning of the terminal catheterizations (arrow). (F) The improvement in the vessel diameter angiographically (arrow) following repeat angioplasty is more modest compared to the change seen following debanding

previously described. Postangioplasty gradients were recorded and angiograms were repeated. Following this procedure, the piglets were transported back to their housing for postprocedure care as previously described. Stenting of the stenotic vessels was considered in cases of stenosis refractory to repeat angioplasty. This was defined as a vessel that continued to meet criteria for recurrent stenosis following maximal balloon diameter angioplasty.

## 2.6 | Final catheterization

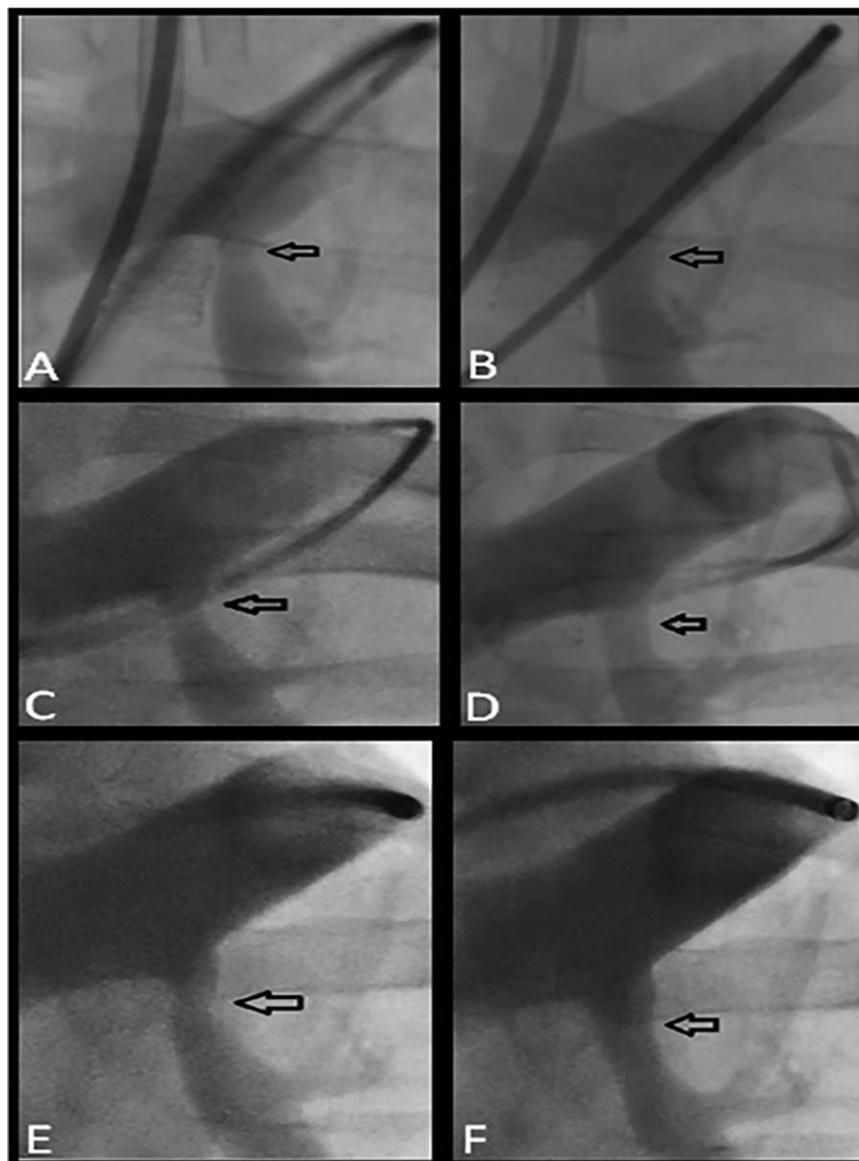
The piglets were allowed to grow to an average human adult size (50–60 kg) at which time a terminal experiment was performed consisting of a cardiac catheterization to evaluate for any residual pulmonary

artery stenosis, and if indicated, angioplasty procedures were performed as previously described in the repeat catheterization stage. At the end of the procedure, the pigs were euthanized and excisional biopsies were taken of the previously banded segments of the pulmonary arteries as previously described for the piglets in the acute arm.

## 2.7 | Histopathology

The vessels specimens were processed in plastic, dehydrated alcohol, cleared with Xylene, infiltrated with Epon spur, cut at 5  $\mu\text{m}$ , and stained with Hematoxylin and Eosin, Trichrome and Von Geison stain (Elastin). Medial dissection was defined as dissection of the tunica media circumferentially along the external elastic lamina. These were graded based





**FIGURE 3** Pulmonary artery debanding of LPA in chronic model. (A) Angiogram demonstrating the LPA band site (arrow) prior to debanding at 7.6 kg. (B) Angiogram immediately following debanding shows near complete resolution of stenosis (arrow). (C) There is residual stenosis (arrow) noted at the beginning of the second catheterization at 26 kg. (D) Angiogram following angioplasty during the second catheterization shows improvement of stenosis. (E) There is significant residual stenosis noted again during the terminal catheterization prior to any intervention (arrow). (F) Repeat angioplasty shows improvement in the LPA stenosis, but there is still significant residual stenosis following intervention in this case

on the extent of dissection and represented as a percentage of the entire tunica media layer. No dissection was scored as 0, for localized dissection as 1, 25–50% dissection as 2, for 50–75% dissection as 3 and for >75% dissection as 4. Radial vessel wall injury was scored as 0 for no injury, 1 for rupture of the internal elastic lamina, 2 for injury to the media, 3 for injury to the external elastic lamina, and 4 for rupture extending up to the adventitia. Controls consisted of normal pulmonary artery segments from piglets of the same age and size for comparison. Scores of 3 and above for dissection and/or radial vessel wall injury were categorized as significant vessel damage. Scores of 0 were categorized as no vessel damage, and scores of 1 and 2 were categorized as insignificant vessel damage.

## 2.8 | Statistical analysis

Continuous data are reported as mean  $\pm$  standard deviation or median with interquartile range (IQR) and categorical data as numbers with percentages.

## 3 | RESULTS

### 3.1 | Catheterization

PA bands were placed in newborn piglets at a mean weight of  $2.56 \pm 0.17$  kg (Table 1). The piglets underwent the first catheterization

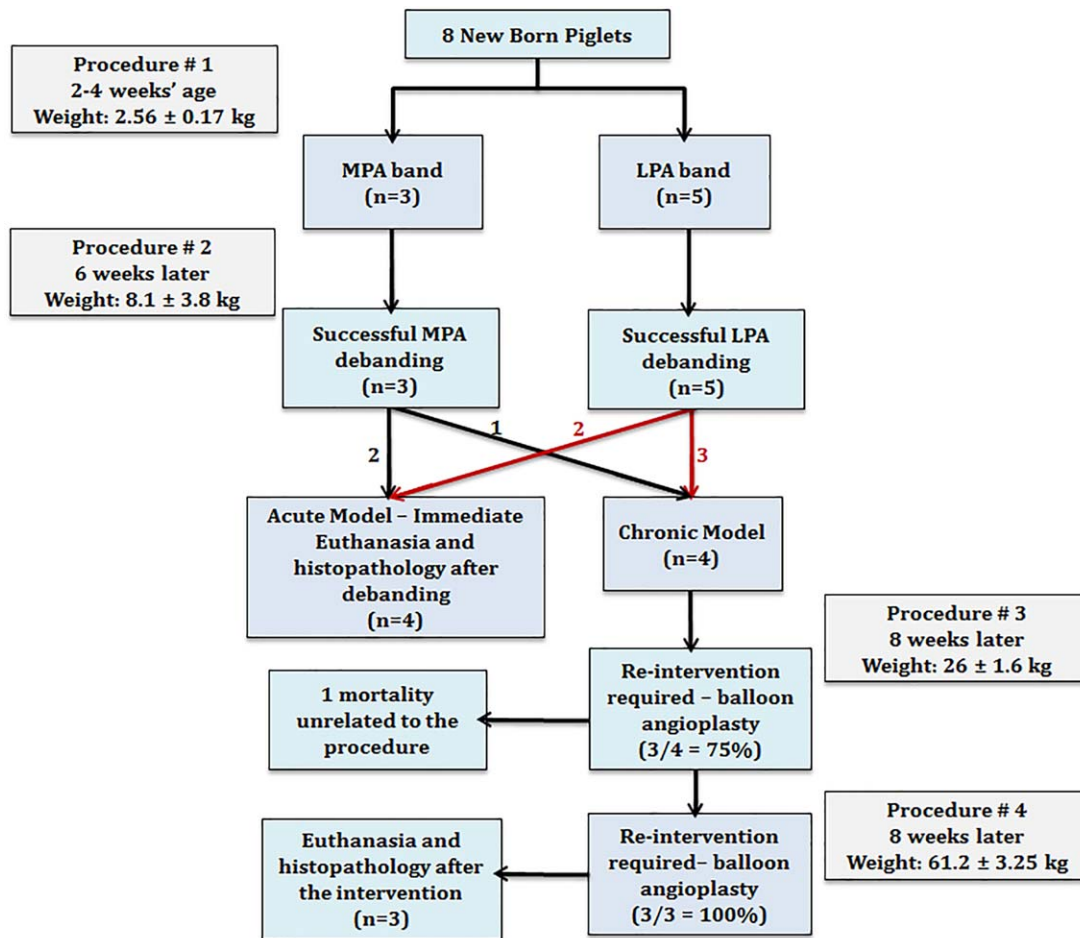
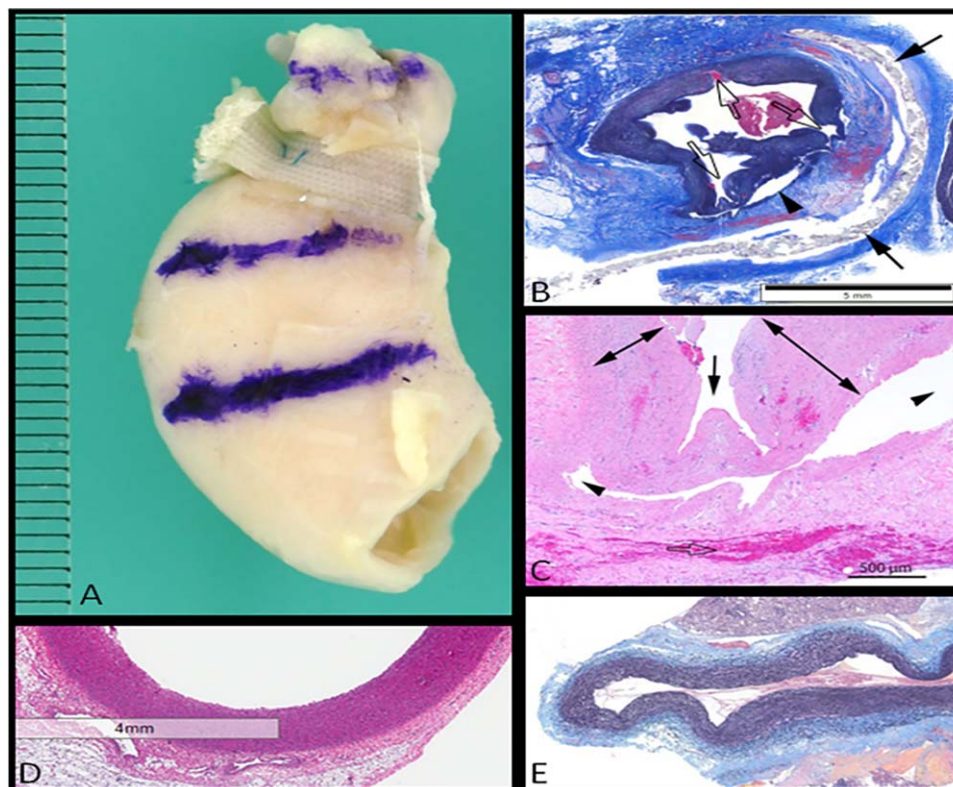


FIGURE 4 Flow diagram demonstrating the experimental methods and outcomes

at an average weight of  $8.1 \pm 3.8$  kg, 6 wk after band placement. The average preintervention gradient across the band was  $17 \pm 6$  mm Hg. The median PAB diameter was 1.9 and 3.3 mm in those with LPA and MPA bands, respectively. The median percent stenosis was 65% (IQR: 58–70). Balloon angioplasty resulted in successful debanding in all eight piglets (Figure 1). The average pressure required to achieve debanding was  $11.7 \pm 2.5$  atm. The mean balloon size used to achieve debanding was 10 mm for MPA bands and for 6 mm LPA bands. The calculated ratio of the balloon size required for debanding to the size of the PAB stenosis was  $2.7 \pm 0.5$ . The ratio of the balloon diameter in relation to the adjacent vessel diameter was  $0.96 \pm 0.2$ . The median percent stenosis decreased to 35% (IQR: 27–56). The median postdebanding gradient was 3.5 mm Hg, which represents a decrease of 80% in the pressure gradient itself compared to preangioplasty gradient values (Table 1).

The four pigs that underwent repeat catheterization 8 wk later at a mean weight of  $26 \pm 1.6$  kg, consisted of three pigs in which the LPA was previously banded and one pig with a previously banded MPA. Three of the four piglets in the chronic model required re-interventions for residual stenosis at the band site with a mean systolic gradient of  $9 \pm 3$  mm Hg across the previously

banded artery (Table 2). The median percent stenosis in these four piglets was 44% (IQR: 27–60). The single pig that did not undergo intervention at this stage had no significant angiographic evidence of residual stenosis (percent stenosis of 23%) and a minimal pressure gradient (6 mm Hg) across the previously banded LPA site (Table 2). Following intervention in the other three piglets, the median systolic gradient was 4 mm Hg (range 0–13 mm Hg) with a percent stenosis of 54% (range 12–58%). Three of the four piglets in the chronic arm survived to the terminal experiment. One piglet died following the second catheterization due to an unrelated event. The average weight at terminal catheterization was  $61.2 \pm 3.25$  kg. There was residual stenosis of the pulmonary artery angiographically (Figures 2 and 3) in all these pigs. This is represented by a median percent stenosis of 33% (range 31–54%). However, the mean systolic gradient prior to intervention across the previously banded sites was only  $6 \pm 0.6$  mm Hg. The median postangioplasty systolic gradient was relatively unchanged at 4 mm Hg (Table 2). However, in one case, there was moderate improvement with near resolution of previously noted vessel stenosis angiographically (Figure 3) represented by a percent stenosis of 12%. The median percent stenosis for all three pigs following the final intervention decreased to 17% (range 12–33%). Lastly, the LPA



**FIGURE 5** Histopathologic findings of debanded pulmonary arteries. (A) Gross specimen of the left pulmonary artery in a 58 kg pig that underwent debanding and two repeat angioplasty procedures. The band is overlying the vessel, but the sutures holding the ends together have been disrupted. This is the only pig in the study with histopathologic evidence of vessel disturbance. (B) Low power microscopy of the left pulmonary artery from this pig. There is grade 2 medial dissection along the external elastic lamina (arrow heads) and grade 2 vessel wall injury as noted by rupture to the level of the media (open arrows). The band is noted by the closed arrows. (C) High power microscopy of the same specimen with the radial injury demonstrated by the arrow and medial dissection noted by the arrow heads. (D) Low power microscopy of an MPA in a pig belonging to the acute arm of the study. (E) LPA specimen from a pig in the chronic arm. (D and E) No evidence of vessel wall injury or medial dissection

diameter adjacent to the previous band location was half the size of the proximal RPA at the time of the terminal experiment ( $50.7 \pm 9.7\%$ ). A flow diagram demonstrating the experimental methods and outcomes are shown in Figure 4.

Long term, the rate of need for reintervention in this pilot study was 86% for residual stenosis. None of the pigs required surgical intervention following band placement. None of the pulmonary arteries required stent implantation to treat residual stenosis.

### 3.2 | Histopathology

Gross examination of the pulmonary artery segments where the PABs had been located revealed no aneurysms, pseudoaneurysms, or vessel rupture in any of the eight pigs. There was one pig that had grade 2 medial dissection of the banded vessel confirmed by both high and low power microscopy (Figure 5) noted acutely after debanding. The same piglet also had grade 2 vessel wall injury, but none of the other piglets had vessel wall injury by high and low power microscopy (Table 3).

**TABLE 3** Histopathologic grading results of pulmonary artery dissection and/or injury

	Grade 0	Grade 1	Grade 2	Grade 3	Grade 4
Medial dissection					
Number of pig specimens <sup>a</sup>	7	0	1	0	0
Radial wall injury					
Description of injury score	No injury	Rupture of the internal elastic lamina	Rupture of the media	<i>Rupture of the external elastic lamina</i>	<i>Rupture extending to the adventitia</i>
Number of pig specimens	7	0	1	0	0

The italics of the table signify the vessel grades (3 and 4) of dissection and injury that were considered significant in this study.

<sup>a</sup>These were the number of pigs out of a total of 8 that met the criteria for each grade of vessel dissection and vessel wall injury based on the histopathologic descriptions provided for each score.



Overall, these microscopic findings accounted for the only complications after endovascular debanding.

## 4 | DISCUSSION

The first study to evaluate transcatheter debanding of PABs was performed in dogs in 1988 by Lindbergh et al. in which eight dogs had MPA bands placed early in life.<sup>3</sup> There was an average decrease of 33% in the main pulmonary artery systolic pressure gradients after debanding.<sup>3</sup>

In 1990, this same group of investigators reported balloon debanding of the MPA in two children at 6 mo and 4 y of age.<sup>4</sup> There were no acute complications postdebanding, and the gradients were almost completely relieved across the previously banded areas in both patients. A more comprehensive study in 2012 by the same group reported main PAB dilation and debanding in 33 children from 1985 to 2007.<sup>5</sup> They reported successful debanding in 14 of the 17 patients with total debanding and 9 of the 16 patients in which they performed stepwise balloon dilation. Of those that underwent intentional total debanding, a significant proportion (6 out of 14) required repeat angioplasties for significant residual gradients. Four patients eventually underwent surgical intervention to alleviate residual PA stenosis. Major complications in that study included death in one patient 2 d after the procedure attributed to pulmonary hypertensive crisis and bleeding from rupture of the pulmonary artery following angioplasty in another patient.<sup>5</sup>

A separate group from the United Kingdom in 2009 reported balloon debanding of the MPA in three children.<sup>6</sup> MPA bands were placed in infancy (5 mo of age or less) and balloon debanding took place at an average of 16 mo thereafter. Debanding was unsuccessful in one patient who became hemodynamically unstable during the procedure. This patient was urgently transferred to the operating room for surgical band removal. The other two patients had successful debanding with a decrease in the mean pullback gradient across the MPA of 38 and 56%, respectively.<sup>6</sup> Follow-up was performed in these two patients at 19 and 20 mo following the procedures, respectively. There were no re-interventions in either case at the time of follow-up.<sup>6</sup>

Although limited, these reports demonstrate the potential clinical use of endovascular pulmonary artery debanding. However, they also highlight certain complications that warrant further investigation into the safety of this procedure. This current study reconfirmed the feasibility of this intervention in an animal model. However, it also provides an objective measure of safety for this procedure through the use of histopathology evaluation, which has not been previously reported. In this swine model, the procedure did not produce any hemodynamically significant arterial dissection or significant blood vessel wall injury acutely. Those piglets in the chronic arm of the study required at least two reinterventions for recurrent stenosis following debanding. Although there were minimal pressure gradients in certain cases, such as the terminal catheterizations, balloon angioplasty was performed due to angiographic evidence of at least moderate pulmonary artery stenosis (Figures 2 and 3). This was especially true for those that had

LPA bands, in which the pressure gradients were small, but the LPA was roughly half the size of the RPA. If this procedure were to become routinely used in clinical practice, long-term monitoring by echocardiogram and repeat catheterizations would be strongly encouraged to evaluate the need for reintervention. We would recommend serial balloon dilation with this procedure. Specifically, balloon diameters may be increased as needed for debanding through upsizing by 2 mm increments up to a maximum balloon diameter that equals the adjacent vessel wall diameter. There may be poststenotic dilation of the immediately adjacent vessel in certain cases and this can be considered a limitation of the study. However, using a more distal segment of a branch pulmonary artery would result in using a much smaller vessel caliber due to normal tapering of these vessels with further branching, which typically occurs shortly after its bifurcation from the main pulmonary trunk.

As in the acute model, there was no evidence of significant vessel wall injury or dissection of the pulmonary arteries in the chronic model despite multiple reinterventions. There was only one pig in the acute model with any degree of vessel dissection and wall injury, but did not meet the criteria for significant based on our grading scale. Overall, the complication rate in this pilot study was 12.5% which consisted of mild medial dissection and mild vessel wall injury in one piglet.

This study has several limitations, the most important of which is the small number of animals used to conduct experiments. This resulted in a wide range of result values in certain cases. Another deficiency is that blood flow distribution between the RPA and the LPA were not measured. This might be a better parameter for evaluating residual pulmonary artery stenosis as compared to gradients or angiographic vessel narrowing. Although this study was not designed to evaluate pulmonary artery growth, the debanded LPAs were found to be roughly half the size of the unbanded RPAs during the terminal catheterization. To our knowledge, there are no available growth curves for pulmonary arteries in the domestic farm pig. Angiographic PA measurements in comparably sized control pigs is likely the best method of determining the effect of endovascular debanding on PA growth, which was not performed in this study. Lastly, although this pilot study has demonstrated that PA debanding is feasible and safe in swine, further experiments are needed to compare this endovascular approach to standard surgical PA debanding.

In addition to the spontaneous closure of muscular VSDs, endovascular PA debanding may be useful in other settings. PABs are currently being used by some groups in patients with congenitally corrected transposition of the great arteries for the purpose of retraining the subpulmonary left ventricle as well as aiding a failing subaortic right ventricle.<sup>11,12</sup> However, in such cases, debanding is likely not as useful as these patients will ultimately require a surgical intervention at the time of band removal. Serial transcatheter band dilation may be more useful in limited scenarios. A more recent development is the use of PAB for left ventricular dilated cardiomyopathy. Preliminary data suggest that in patients where right ventricular function is preserved, there is an improvement in left ventricular and mitral valve function following PAB.<sup>13</sup> In these limited scenarios, endovascular debanding is an

appealing alternative where there is likely no other indication for surgical intervention.

## 5 | CONCLUSION

Endovascular PA debanding is both feasible and safe in a swine model. However, reinterventions may be necessary to treat recurrent stenosis and for optimal pulmonary artery growth. Future studies are needed to compare this endovascular approach to standard surgical PA debanding. This catheter-based therapy may provide a less-invasive alternative to surgery in infants.

## CONFLICT OF INTEREST

No author has any conflict of interest to disclose.

## AUTHOR CONTRIBUTIONS

*Concept/design, conduct of experiments, data collection and interpretation, and drafting the manuscript:* Perez

*Data collection and interpretation and drafting the manuscript:* Briceño-Medina

*Conduct of experiments and drafting the manuscript:* Susheel Kumar

*Conduct of experiments, data interpretation, and drafting the manuscript:* Hoskoppal

*Conduct of experiments:* Akkhwattanangkul

*Conduct of experiments, data collection:* Allen

*Concept/design, critical revision, and approval of manuscript:* Knott-Craig

*Concept/design, critical revision, and approval of manuscript:* Waller

*Concept/design, conduct of experiments, data interpretation, and drafting and approval of manuscript:* Sathanandam

## REFERENCES

- [1] Muller WH, Jr, Danimann JF. Jr., The treatment of certain congenital malformations of the heart by the creation of pulmonic stenosis to reduce pulmonary hypertension and excessive pulmonary blood flow. *Surg Gynecol Obstet.* 1952;95(2):213–219.
- [2] Oppido G, Pace Napoeone C, Turci S, Angeli E, Gargiulo G. Pulmonary artery debanding. *Multimedia Manual Cardiothorac Surg.* 2012; 2012:mms009.
- [3] Lindberg H, Smevik B, Bjørnstad PG, et al. Balloon dilatation of pulmonary artery banding in dogs: an experimental study. *Cardiovasc Intervent Radiol.* 1988;11(3):150–154.
- [4] Bjørnstad PG, Lindberg HL, Smevik B, Rian R, Sørland SJ, Tjønneland S. Balloon debanding of the pulmonary artery. *Cardiovasc Intervent Radiol.* 1990;13(5):300–303.
- [5] Holmström H, Bjørnstad PG, Smevik B, Lindberg H. Balloon dilatation of pulmonary artery banding: Norwegian experience over more than 20 years. *Eur Heart J.* 2012;33(1):61–66.
- [6] Morgan GJ, Chen Q, Parry A, Martin R. Balloon debanding the pulmonary artery: in vitro studies and early clinical experience. *Congenit Heart Dis.* 2009;4(4):273–277.
- [7] Akintuerk H, Michel-Behnke I, Valeske K, et al. Stenting of the arterial duct and banding of the pulmonary arteries: basis for combined Norwood stage I and II repair in hypoplastic left heart. *Circulation.* 2002;105(9):1099–1103.
- [8] Venugopal PS, Luna KP, Anderson DR, et al. Hybrid procedure as an alternative to surgical palliation of high-risk infants with hypoplastic left heart syndrome and its variants. *J Thorac Cardiovasc Surg.* 2010;139(5):1211–1215.
- [9] Hannon JP, Bossone CA, Wade CE. Normal physiological values for conscious pigs used in biomedical research. *Lab Anim Sci.* 1990;40(3):293–298.
- [10] Schinckel AP, de Lange CF. Characterization of growth parameters needed as inputs for pig growth models. *J Anim Sci.* 1996;74(8): 2021–2036.
- [11] Murtuza B, Barron DJ, Stumper O, et al. Anatomic repair for congenitally corrected transposition of the great arteries: a single-institution 19-year experience. *J Thorac Cardiovasc Surg.* 2011;142(6):1348–1357.
- [12] Metton O, Gaudin R, Ou P, et al. Early prophylactic pulmonary artery banding in isolated congenitally corrected transposition of the great arteries. *Eur J Cardiothorac Surg.* 2010;38(6):728–734.
- [13] Schranz D, Rupp S, Müller M, et al. Pulmonary artery banding in infants and young children with left ventricular dilated cardiomyopathy: a novel therapeutic strategy before heart transplantation. *J Heart Lung Transplant.* 2013;32(5):475–481.

**How to cite this article:** Perez M, Kumar TS, Hoskoppal D, et al. Acute and long-term effects of endovascular debanding of pulmonary arteries in a swine model. *Congenital Heart Disease.* 2017;12:340–349. <https://doi.org/10.1111/chd.12449>